

## Optical coherence tomography biomarkers after intravitreal anti-vascular endothelial growth factor for diabetic macular edema

Pola S. Soliman<sup>1</sup>, Amr A. Osman<sup>2</sup>, Rana A. Abdel Fattah<sup>3</sup>, Gihan M. Shokier<sup>4</sup>

<sup>1</sup>: Assistant Lecturer of ophthalmology, Faculty of Medicine, Cairo University, Egypt

<sup>2</sup>: Professor of ophthalmology, Faculty of Medicine, Cairo University, Egypt

<sup>3</sup>: Lecturer of ophthalmology, Faculty of Medicine, Cairo University, Egypt

<sup>4</sup>: Lecturer of ophthalmology, Faculty of Medicine, Cairo University, Egypt

**Corresponding Author:** Name: Gihan Mohamad Reda Elsayed Shokier, MD. Academic position: Lecturer of Ophthalmology, Cairo University, Egypt. Address: 2 Misr Tameer buildings , zahraa Elmaadi, Cairo, Egypt. Email: [gshokier42@gmail.com](mailto:gshokier42@gmail.com) Cellular: +201010592536, Fax number: +237496302, ORCID ID: 0000-0002-9914-9029

Received: 2-12-2022, Accepted: 30-5-2023, Published online:16-9-2023

EJO(MOC) 2023;3(3):127-136.

**Running Title:** OCT biomarkers after intravitreal anti-VEGF for DME

### ABSTRACT

**Objective:** The study aims to determine the association between the functional and the anatomical responses after intravitreal anti- VEGF injection for cases of non-tractional DME and the baseline SD-OCT biomarkers.

**Study Design:** a prospective, single-center, observational study.

**Patients and Methods:** The study included 51 eyes of 35 Patients with non-tractional DME with central subfield thickness (CST) of more than 250 micrometers. Baseline SD-OCT biomarkers and BCVA were detected. All patients received monthly intravitreal anti-VEGF injections of bevacizumab 1.25 mg/0.05 ml for 3 months with reassessment of BCVA and OCT parameters one month after the 3rd injection.

**Results:** Of the 51 eyes, 15 were functional responders and 28 were anatomical responders. There were a statistically significant association between the functional response and combined DME ( $p= 0.015$ ) and between it and the subretinal fluid ( $p= 0.050$ ), while on associating functional response to DRIL, hyperreflective foci, ellipsoid zone integrity and ELM integrity; there were statistically insignificant associations ( $p =0.884, 0.409, 0.971$  and  $0.971$  respectively). A statistically significant association was found between the anatomical response and the subretinal fluid ( $p = 0.004$ ) with no statistically significant associations between it and other OCT biomarkers.

**Conclusion:** Although multiple OCT biomarkers were used as predictors for the functional response after IVI of anti-VEGF in cases of non-tractional diabetic DME, only the type of macular edema and the presence of subretinal fluid were with significant association with the functional response in this study. Further larger studies with longer duration are needed

Keywords: OCT biomarkers - DME - intravitreal anti-VEGF.

### INTRODUCTION:

Complications from diabetes mellitus (DM) are common causes of losing vision. A common complication of DM is diabetic macular edema (DME) due to leakage from retinal vasculature<sup>1-5</sup>. DME affects about 30% of all patients with DM for more than 20 years<sup>6</sup>. The detection of reliable markers of the present and future visual acuity (VA) in DME patients is considered of highly medical importance. Patient age, severity of diabetic retinopathy and existence of epiretinal membrane or hard exudation were used as predictors for the visual outcome in diabetic macular edema<sup>7</sup>. Spectral domain–optical coherence tomography (SD-OCT) is a non-invasive imaging tool providing reliable images of retinal anatomy. It allows measurement of central macular thickness which was correlated in many studies with the visual outcome in cases of DME<sup>8-12</sup>. Ever since screening of

**Egyptian Journal of Ophthalmology, a publication of Mansoura Ophthalmic Center.**

Address: Mansoura Ophthalmic Center, Mansoura University, Mansoura, Egypt.

Tel. 0020502202064. Fax. 0020502202060.

E-mail: [ejo@mans.edu.eg](mailto:ejo@mans.edu.eg)

patients with DME by SD-OCT biomarkers became into focus. These biomarkers include pattern of macular edema, disorganization of inner retinal layers (DRIL), subretinal fluid, hyper reflective foci, ellipsoid zone (EZ) integrity and external limiting membrane (ELM) integrity. SD-OCT biomarkers assumed to be significant predictors for progression of the disease and also to be important indicators of the current and the future visual outcome in eyes with DME<sup>13,14</sup>.

The aim of the study is to determine the association between the functional and the anatomical responses after treatment with intravitreal anti- VEGF injection for cases of non-tractional diabetic macular edema and the baseline SD-OCT biomarkers.

#### **PATIENTS AND METHODS:**

This was a prospective, observational, analytical, non-randomized study applied on 51 eyes of 35 diabetic patients presented to the retina subspecialty clinic in Kasr Al Ainy hospital, Cairo University from February 2018 to September 2018. All selected patients received an explanation of the study aims and design. An informed consent was obtained from all patients. All procedures performed in the study followed the 1964 Helsinki declaration and its later amendments.

#### **Study Population:**

#### **Inclusion Criteria:**

Patients with non-tractional DME with central sub field thickness (CST) of more than 250 micrometers that was documented by SD-OCT. They were all candidate for anti-VEGF intravitreal injection (IVI) as a treatment for DME.

#### **Exclusion Criteria:**

Patients who were treated with retinal laser photocoagulation or intravitreal anti-VEGF injection within the last 6 months, patients with ischemic maculopathy detected by fundus fluorescein angiography (FFA), patients with media opacity significantly reducing OCT scan signal level and patients who underwent cataract surgery within the last 6 months were excluded from the study.

#### **Data collection:**

History (including; personal history, present history, history of systemic diseases, history of ocular diseases, history of

ocular treatments or previous surgery) was taken from all patients. All patients underwent a full comprehensive ophthalmological examination in the form of best corrected visual acuity (BCVA) using Snellen's chart, slit lamp examination of the anterior segment, fundus examination by binocular indirect slit lamp biomicroscopy (+90D or +78D), IOP measurement by Goldmann applanation tonometry. HbA1C (glycosylated hemoglobin) was ordered and FFA was done to exclude ischemic maculopathy for all patients.

Baseline SD-OCT was done using RTVue 6.2 (optovue Inc, Fremont, CA) for all patients before the injection of intravitreal anti-VEGF. Enhanced macular map 5 (EMM5) scan was used to detect central sub field thickness (CST) which is measured according to this device as the distance between the vitreoretinal interface (internal limiting membrane) and the outer border of the photoreceptor outer segment. The SD-OCT radial scan was used to detect the pattern of macular edema, disorganization of retinal inner layers (DRIL), subretinal fluid, hyper-reflective foci, ellipsoid zone integrity and external limiting membrane integrity. All patients underwent monthly intravitreal anti-VEGF injections of bevacizumab 1.25 mg/0.05 ml (Avastin) for 3 months.

Reassessment of BCVA and OCT parameters were carried out one month after the 3rd injection.

#### **Outcome Measures:**

- 1- Detection of the functional responders one month after the third injection of intravitreal bevacizumab 1.25 mg/0.05 ml (Avastin). the functional responders were defined as those who gained 2 lines of BCVA (measured by Log MAR).
- 2- Detection of the association between the functional response and between the baseline OCT biomarkers of diabetic macular edema.
- 3- Detection of the anatomical responders one month after the third injection of intravitreal bevacizumab 1.25 mg/0.05 ml (Avastin). The anatomical responders were defined as those who had decrease of central subfield thickness by 10%.

4- Detection of the association between the anatomical response and between the baseline OCT biomarkers of diabetic macular edema.

#### Statistical analysis:

The sample size was calculated by cox proportional hazards model. Data were entered and coded using the statistical package SPSS (Statistical Package for the Social Sciences) version 25. Data was summarized using median, minimum, maximum, mean and standard deviation in quantitative data and for categorical data; frequency (count) and relative frequency (percentage) were used. The non-parametric Kruskal-Wallis and Mann-Whitney tests were used for Comparisons between quantitative variables. The non-parametric Wilcoxon signed rank test was used for comparison of serial measurements within each patient. Chi

square test was performed for comparing categorical data. When the expected frequency is less than 5, exact test was used instead. Correlation between quantitative variables was done using Spearman correlation coefficient. P-values less than 0.05 were considered statistically significant.

#### RESULTS:

Fifty one eyes of 35 patients were included in this study. The mean age of the patients was 56.37±8.12 years (range,43 to 81 years). The mean duration of diabetes was 12.75±8.32 years (range, 0.17 to 40 years). The mean HbA1c was 8.3±1.82% (range, 5.6 to 13.5%). Eleven eyes of 7 patients were pseudophakic with a mean duration of phacoemulsification surgery of 3.11±2.78 years (range,0.58 to7 years). The demographic and clinical data of the patients are shown in table (1).

**Table (1): the demographic and clinical data of the patients (n=51 eyes of 35 patients):**

		Count	%
Sex	M	15	42.9%
	F	20	57.1%
Type of DM	type 2	35	100.0%
Treatment of DM	Insulin	20	57.1%
	OHD	15	42.9%
History of intraocular surgery	Yes	11	21.6%
	No	40	78.4%
History of IVI or Laser or no history	Laser	8	15.7%
	IVI	6	11.8%
	laser and injections	2	3.9%
Laterality	None	35	68.6%
	OS	27	52.9%
Retinopathy severity	OD	24	47.1%
	PDR	6	11.8%
	NPDR	45	88.2%
Lens status	Clear	20	39.2%
	Pseudophakic	11	21.6%
	IMSC	20	39.2%

M, male; F, female; DM, diabetes mellitus; OHD: oral hypoglycemic drugs, IVI, intravitreal injection; OD, oculus dexter ; OS, oculus sinister; PDR, proliferative diabetic retinopathy; NPDR, non proliferative diabetic retinopathy; IMSC, immature senile cataract.

The pre injection BCVA (Log MAR), Pre injection CST, Post injection BCVA (Log MAR) and Post injection CST of the patients are summarized in table (2)

**Table (2): The pre injection BCVA, Pre injection CST, Post injection BCVA and Post injection CST of the patients (n=51 eyes):**

	Mean	Standard Deviation	Median	Minimum	Maximum
<b>pre injection BCVA (Log MAR)</b>	0.79	0.38	0.78	0.18	1.80
<b>Pre injection CST (µm)</b>	443.39	130.51	423.00	289.00	826.00
<b>Post injection BCVA (Log MAR)</b>	0.62	0.35	0.60	0.00	1.30
<b>Post injection CST (µm)</b>	366.90	115.22	349.00	179.00	719.00

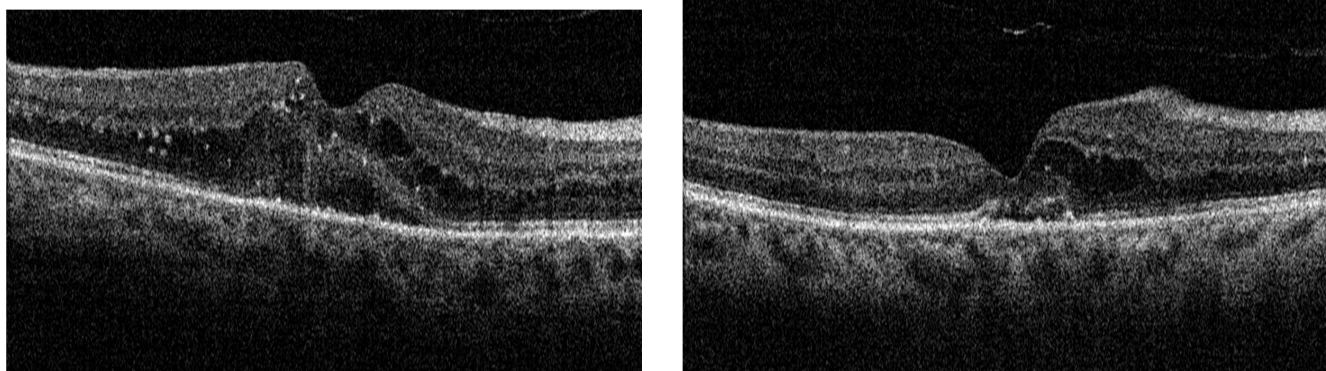
BCVA, best corrected visual acuity; logMAR, logarithm of the minimal angle of resolution; CST, central subfield thickness; µm, micrometer.

The Pre injection and the Post injection OCT morphological features of all patients are included in table (3) (figures 1,2,3)

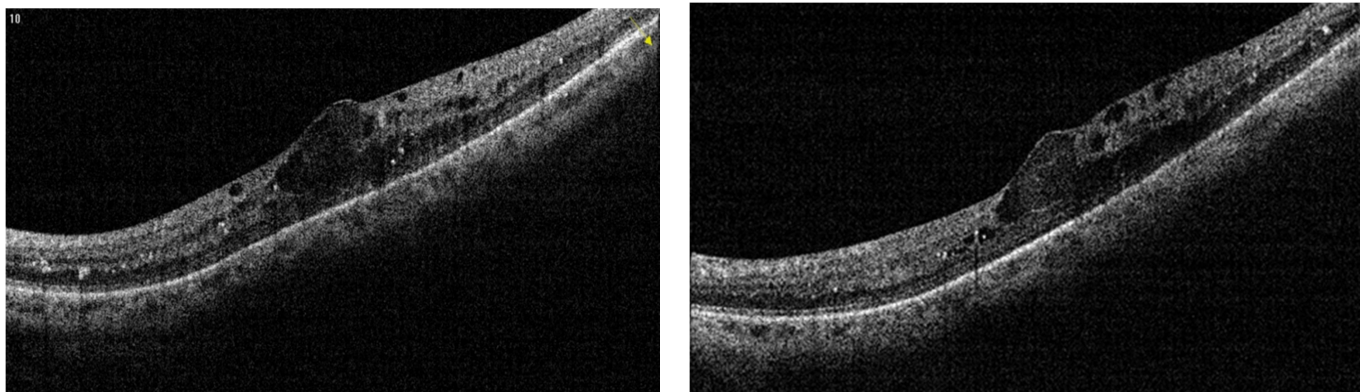
**Table (3): The Pre injection and the Post injection OCT morphological features of the patients (n=51 eyes):**

		Pre-injection Count	Pre injection %	Post injection Count	Post injection %
<b>Pattern of edema</b>	<b>Diffuse</b>	5	9.8%	7	13.7%
	<b>Cystoid</b>	18	35.3%	17	33.3%
	<b>Combined</b>	28	54.9%	27	52.9%
<b>DRIL</b>	<b>Yes</b>	28	54.9%	28	54.9%
	<b>No</b>	23	45.1%	23	45.1%
<b>Subretinal fluid</b>	<b>Yes</b>	20	39.2%	9	17.6%
	<b>No</b>	31	60.8%	42	82.4%
<b>Hyperreflective foci</b>	<b>Yes</b>	43	84.3%	47	92.2%
	<b>No</b>	8	15.7%	4	7.8%
<b>Ellipsoid zone integrity</b>	<b>Interrupted</b>	27	52.9%	29	56.9%
	<b>Intact</b>	24	47.1%	22	43.1%
<b>ELM integrity</b>	<b>Interrupted</b>	27	52.9%	29	56.9%
	<b>Intact</b>	24	47.1%	22	43.1%

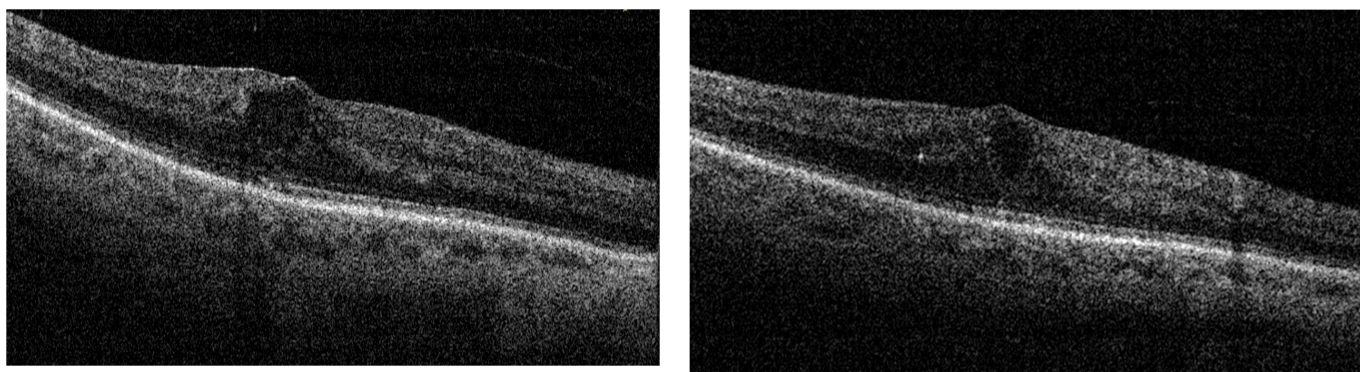
DRIL, disorganization of inner retinal layers ; ELM, external limiting membrane.



**Figure (1):** pre-injection OCT of an eye with combined edema, hyperreflective foci, interruption of EZ and ELM and subretinal fluid (left ). Post-injection OCT with decreased edema and decreased subretinal fluid (right). This eye was functional responder (pre-injection BCVA was 1.8 and post-injection BCVA was 0.78) and anatomical responder (pre-injection CST was 414  $\mu\text{m}$  and post-injection CST was 256  $\mu\text{m}$ ).



**Figure (2):** pre-injection OCT of an eye with DRIL, cystoid edema and hyperreflective foci (left ). Post-injection OCT with mild decrease of edema (right). This eye was functional responder (pre-injection BCVA was 0.6 and post-injection BCVA was 0.3) and anatomical responder (pre-injection CST was 434  $\mu\text{m}$  and post-injection CST was 370  $\mu\text{m}$ ).



**Figure (3):** Pre-injection OCT of an eye with cystoid edema (left ). Post-injection OCT with persistence of edema (right). This eye was functional non responder (pre-injection BCVA was 0.78 and post-injection BCVA was 0.78) and anatomical non responder (pre-injection CST was 349  $\mu\text{m}$  and post-injection CST was 375  $\mu\text{m}$ ).

The count and the percentage of functional and the anatomical responders are shown in table (4).

**Table (4) Count and percentage of the functional and anatomical responders (n=51 eyes):**

		Count	%
<b>Functional responder</b>	<b>Yes</b>	15	29.4%
	<b>No</b>	36	70.6%
<b>Anatomical responder</b>	<b>Yes</b>	28	54.9%
	<b>No</b>	23	45.1%

A statistically significant association was found between the functional response and pre-injection BCVA ( $P=0.015$ ), the better the pre-injection BCVA, the better the functional response. There was statistically insignificant association between the functional response and the pre-injection CST ( $P=0.942$ ).

The relation between the functional response and the type of treatment used for DM showed that there was a statistically significant relation between the functional response and patients treated with insulin ( $p=0.047$ ), while on relating the functional response to age, duration of DM, HbA1c, sex, history of intraocular surgery, history of laser or IVI, eye laterality, retinopathy severity and lens status, there were statistically insignificant relations ( $P=0.221, 0.505, 0.356, 0.743, 0.141, 0.311, 0.562, 1$  and  $0.252$  respectively).

#### **The association between the functional response and the baseline SD-OCT biomarkers:**

Regarding the association between the functional response and baseline OCT morphological features, There was a statistically significant association between the functional response and combined DME ( $p=0.015$ ) and between it and subretinal fluid ( $p=0.05$ ), while on associating functional response to DRIL, hyperreflective foci, ellipsoid zone integrity and ELM integrity; there were statistically insignificant associations ( $p=0.884, 0.409, 0.971$  and  $0.971$  respectively).

There were statistically insignificant associations between the anatomical response and the pre-injection BCVA and the pre-injection CST ( $p=0.270$  and  $0.252$ ).

The anatomical response was better in absence of history of surgery, history of laser or IVI and in phakic patients ( $P=0.014, 0.018$  and  $0.028$  respectively), while on relating

anatomical response to age, duration of DM, HbA1c, sex, treatment of DM, eye laterality and retinopathy severity, there were statistically insignificant relations ( $P=0.425, 0.580, 0.824, 0.275, 0.788, 0.642$  and  $1$  respectively).

#### **The association between the anatomical response and the baseline SD-OCT biomarkers:**

Regarding the association between the anatomical response and baseline OCT morphological features. There was a statistically significant association between the anatomical response and presence of subretinal fluid ( $p=0.004$ ), while on associating anatomical response to the pattern of edema, DRIL, hyperreflective foci, ellipsoid zone and ELM integrity, there were statistically insignificant associations ( $P=0.320, 0.180, 0.422, 0.921$  and  $0.921$  respectively).

#### **DISCUSSION:**

DME is an important cause of loss of vision in patients with diabetes mellitus whether insulin-dependent or non-insulin-dependent. Diabetic macular edema can develop at any stage of retinopathy. Gradual onset of blurring of vision is usually the early presenting symptom of most patients. With the progression of the disease, profound visual loss can develop with increased macular thickness and cysts formation. Specialized techniques such as SD-OCT have become an important diagnostic tool for the diagnosis and management of this condition<sup>15</sup>.

With the improved visualization of retinal anatomy offered by OCT, some of the OCT parameters could be used as predictors of visual outcome with various treatment methods. Some patients with DME show poor visual outcome despite complete resolution of edema with good anatomical response<sup>8</sup>. Our study aimed to determine if certain SD-OCT findings can be used as biomarkers to predict the final visual outcome in eyes with DME after treatment with anti-VEGF therapy. The OCT-based biomarkers included in our study were the pattern of macular edema, DRIL, subretinal fluid, hyperreflective foci, and the integrity of both ellipsoid zone and external limiting membrane.

51 eyes were prospectively observed. All eyes were subjected to full ophthalmological examination and OCT imaging of the macula; then they received monthly

intravitreal anti-VEGF injections (bevacizumab 1.25 mg/0.05ml) for 3 months, followed by reassessment of the OCT parameters and BCVA one month after the 3rd injection. Functional responders were defined as those eyes that gained 2 lines of BCVA (measured by Log MAR), while anatomical responders were defined as those eyes that had reduction of central subfield thickness by 10%. Functional responders were 15 eyes (29.4%) and functional non responders were 36 eyes (70.6%). On the other hand, anatomical responders were 28 eyes (54.9 %) and anatomical non responders were 23 eyes (45.1%).

In our study, there was a statistically significant association between the functional response and pre-injection BCVA. the better the pre-injection BCVA , the better the functional response .This was in contrast to a study by Santos et al. in which 67 eyes were injected with ranibizumab; no difference was found across the different functional response groups (poor, moderate and good responders) in relation to the baseline BCVA<sup>16</sup>.

Additionally, a significant difference between functional responders and non responders was found regarding the type of anti-diabetic treatment; with a higher likelihood of being a functional responder if the patient was on insulin rather than oral hypoglycemic drugs. This result was in contrary to the result of Matsuda et al. study, which showed no difference in visual outcome between patients treated with oral hypoglycemic drugs and patients treated with insulin<sup>17</sup>.

Associations between BCVA and OCT parameters such as presence of subretinal fluid, hyperreflective foci, intraretinal cysts, disruption of ELM and ellipsoid zone in eyes with DME have been suggested by some studies<sup>18-20</sup>. These associations have not been reliable enough to predict visual acuity and most of the reported studies were retrospective in mixed treatment cohorts. In our study, a statistically significant association was found between the functional response and pattern of DME, where the combined edema was the most common pattern in the functional responder group. This result was in contrary with Santos et al. that found no such difference between the different patterns<sup>16</sup>. On the other hand, Alkuraya et al. declared that diffuse edema has a better visual outcome than cystoid

edema<sup>11</sup>. Also, Yaamoto and his colleagues reported significantly worse visual acuity with diabetic cystoid macular edema than with diffuse retinal swelling with no cystoid edema<sup>21</sup>.

In the current study, there was a statistically significant association between the functional response and presence of subretinal fluid. However, Santos, et al<sup>16</sup> ,Sun et al<sup>22</sup> and Eraslan et al<sup>23</sup> concluded that the association between the subretinal fluid and the functional response was not statistically significant. Sophie et al. declared that eyes with subretinal fluid had a better visual outcome<sup>20</sup>. However, Alkuraya et al. declared that eyes with subretinal fluid had a worse visual outcome<sup>11</sup>.

On the other hand, no statistically significant association was encountered between the functional response on one hand and DRIL, hyperreflective foci, EZ integrity and ELM integrity on the other hand. These findings were in agreement with what was found by Sun et al. who did not find significant associations between VA and neither of hyperreflective foci nor ELM disruption<sup>24</sup>.

However, other studies<sup>22,24</sup> have identified DRIL, affecting 50% of the 1-mm central retinal zone , as a parameter with high association with current and future vision loss in eyes with DME. They also reported that the increase of DRIL during treatment was associated with decrease of BCVA. But again, these data were obtained retrospectively as part of routine clinical care rather than being part of a research protocol.

Maheshwary and his associates<sup>25</sup> found a statistically significant correlation between the percentage of ellipsoid zone disruption and BCVA. Also, Eraslan et al.<sup>23</sup> and Ito et al.<sup>26</sup> found that there was a strong correlation between VA and the integrity of the ELM and ellipsoid zone unlike the current study in which there was no such association.

In our study, there was no statistically significant association between the presence of hyperreflective foci and the functional response. This agreed with Sun et al.<sup>24</sup> and a meta analysis of Ganne et al<sup>27</sup>. Unlike Uji et al. who declared that hyperreflective foci is closely associated with EZ and ELM disruption and decreased BCVA<sup>28</sup>.

Larger hyperreflective foci found in outer retinal layers on SD-OCT were assumed to be related to microexudates, whereas the fine hyperreflective dots, which are scattered through all retinal layers, correspond to activated microglia, this was supported by a greater decrease in the number of fine hyperreflective dots in patients treated with dexamethasone implants compared to anti-VEGF agents due to the anti-inflammatory effect of dexamethasone<sup>29</sup>.

Regarding the anatomical response, on relating it to history of previous procedures, we found that a larger percentage of patients who underwent cataract extraction or received IVI or laser treatment showed less reduction of CST than those who did not receive any previous procedures. On associating the anatomical response to the subretinal fluid, we found that the presence of subretinal fluid was a good predictor for a reduction in CST. Also, Sophie et al. reported that in ranibizumab-treated patients, the decrease of CST was predicted by prominent subretinal fluid causing large neurosensory detachment<sup>20</sup>.

Limitations of our study were the relatively small sample size and the short follow-up period although certain studies found that early visual response is a beneficial factor in predicting a long-term visual response<sup>30</sup>. Longer prospective studies with larger sample size are needed to evaluate variable OCT biomarkers.

**Conflict of interest:** The authors declare that they have no conflict of interest.

**Declarations:**

**Acknowledgements:** None

**Financial disclosure:** None of the authors has any financial disclosures to make.

**Author contributions:** PS recruited patients, collected the data, and tabulated the results. AO contributed to the design and the conceptualization of the study. RA contributed to data analysis and references collection. GS contributed to the design and the conceptualization of the study, wrote and revised the manuscript. All authors read and approved the final manuscript.

**Funding:** This research did not receive any specific grant from funding agencies in the public, commercial, or not-for-profit sectors

**Conflict of interest:** The authors declare that they have no conflict of interest.

**Ethical approval:** All procedures performed in the study followed the 1964 Helsinki declaration and its later amendments.

**Informed consent:** Informed consent was obtained from all individual participants included in the study.

**REFERENCES:**

1. Klein BE. Overview of epidemiologic studies of diabetic retinopathy. *Ophthalmic Epidemiology*. 2007;14(4):179-183.
2. Ciulla TA, Amador AG, Zinman B. Diabetic retinopathy and diabetic macular edema: pathophysiology, screening, and novel therapies. *Diabetes Care*. 2003;26(9):2653–2664.
3. Xie XW, Xu L, Wang YX, Jonas JB. Prevalence and associated factors of diabetic retinopathy. The Beijing Eye Study 2006. *Graefes Archive for Clinical and Experimental Ophthalmology*. 2008; 246(11):1519-1526.
4. Boyer DS, Hopkins JJ, Sorof J, Ehrlich JS. Anti-vascular endothelial growth factor therapy for diabetic macular edema. *Ther Adv Endocrinol Metab*. 2013;4(6):151-69.
5. Das A, McGuire PG, Rangasamy S. Diabetic macular edema: pathophysiology and novel therapeutic targets. *Ophthalmology*. 2015; 122(7):1375-1394.
6. Klein R, Klein BE, Moss SE, Davis MD, De Mets DL. The Wisconsin Epidemiologic Study of Diabetic Retinopathy. IV. diabetic macular edema. *Ophthalmology*. 1984; 91(12):1464-1474.
7. Bressler S, Qin H, Beck R, Chalam K, Kim J, Melia M, Wells J. Factors Associated with changes in visual acuity and OCT thickness at 1 year after treatment for diabetic macular edema with Ranibizumab. *Arch Ophthalmol*. 2012 ;130(9): 1153-1161.
8. Browning DJ, Glassman AR, Aiello LP, Beck RW, Brown DM, Fong DS, et al. Diabetic Retinopathy Clinical Research Network. Relationship between optical coherence tomography-measured central retinal thickness and visual acuity in diabetic macular edema. *Ophthalmology*. 2007; 114(3):525-536.



9. Aronson JK. Biomarkers and surrogate endpoints. *Br J Clin Pharmacol.* 2005; 59:491-4.
10. Pelosini L, Hull CC, Boyce JF, McHugh D, Stanford MR, Marshall J. Optical coherence tomography may be used to predict visual acuity in patients with macular edema. *Invest Ophthalmol Vis Sci.* 2011; 52:2741-8.
11. Alkuraya H, Kangave D, El-Asrar AM. The correlation between optical coherence tomographic features and severity of retinopathy, macular thickness and visual acuity in diabetic macular edema. *Int Ophthalmol.* 2005; 26:93-99.
12. Ruia S, Saxena S, Prasad S, Sharma SR, Akduman L, Khanna VK. Correlation of biomarkers thiobarbituric acid reactive substance, nitric oxide and central subfield and cube average thickness in diabetic retinopathy: a cross-sectional study. *Int J Retina Vitreous.* 2016;2:8.
13. Markan A, Agarwal A, Arora A, Bazgain K, Rana V, Gupta V. Novel imaging biomarkers in diabetic retinopathy and diabetic macular edema. *Therapeutic Advances in Ophthalmology.* 2020;12: 2515841420950513.
14. Tao LW, Wu Z, Guymer RH, Luu CD. Ellipsoid zone on optical coherence tomography: a review. *Clinical & Experimental Ophthalmology.* 2016;44(5):422-430.
15. Sakamoto A, Nishijima K, Kita M, Oh H, Tsujikawa A, and Yoshimura N. Association between foveal photoreceptor status and visual acuity after resolution of diabetic macular edema by pars plana vitrectomy. *Graefes Arch Clin Exp Ophthalmol.* 2009; 247(10):1325-1330.
16. Santos AR, Costa MA, Schwartz C, Alves D, Figueira J, Silva R, et al. Optical coherence tomography baseline predictors for initial best corrected visual acuity response to intravitreal anti-vascular endothelial growth factor treatment in eyes with diabetic macular edema. *Retina.* 2018;38(6): 1110-1119.
17. Matsuda S, Tam T, Singh RP, Kaiser PK, Petkovsek D, Zanella MT, et al. Impact of insulin treatment in diabetic macular edema therapy in type 2 diabetes. *Can J diabetes.* 2015;39(1):73-77.
18. Murakami T, Nishijima K, Akagi T, Uji A, Horii T, Ueda- Arakawa N, et al. Optical coherence tomographic reflectivity of photoreceptors beneath cystoid spaces in diabetic macular edema. *Investigative Ophthalmology and Visual Science.* 2012; 53:1506-1511.
19. Shin HJ, Lee SH, Chung H, and Kim HC. Association between photoreceptor integrity and visual outcome in diabetic macular edema. *Graefes Arch Clin Exp Ophthalmol.* 2012; 250(1): 61-70.
20. Sophie R, Lu N, Campochiaro PA. Predictors of functional and anatomic outcomes in patients with diabetic macular edema treated with ranibizumab. *Ophthalmology.* 2015;122(7): 1395-1401.
21. Yamamoto S, Yamamoto T, Hayashi M, Takeuchi S. Morphological and functional analyses of diabetic macular edema by optical coherence tomography and multifocal electroretinograms. *Graefes Arch Clin Exp Ophthalmol.* 2001;239(2):96-101.
22. Sun JK, Lin MM, Lammer J, Prager S, Sarangi R, Silva PS ,et al. Disorganization of retinal inner layers as a predictor of visual acuity in eyes with center involved diabetic macular edema. *JAMA Ophthalmol.* 2014;132(11):1309-1316.
23. Eraslan S, Yıldırım Ö, Dursun Ö, Dinç E, Temel GO. Relationship between final visual acuity and optical coherence tomography findings in patients with diabetic macular edema undergoing anti-VEGF therapy. *Turk J Ophthalmol.* 2020;50(3):163-168.
24. Sun JK, Radwa SH, Soliman AZ, Lammer J, Lin MM, Prager SG, et al. Neural retinal disorganization as a robust marker of visual acuity in current and resolved diabetic macular edema. *Diabetes.* 2015;64(7):2560-70.
25. Maheshwary AS, Oster SF, Yuson RMS, Cheng L, Mojana F, Freeman WR. The association between percent disruption of the photoreceptor inner segment-outer segment junction and visual acuity in diabetic macular edema. *Am J Ophthalmol.* 2010;150(1):63-67.
26. Ito SI, Miyamoto N, Ishida K, Kurimoto Y. Association between external limiting membrane status and visual acuity in diabetic macular edema. *Br J Ophthalmol.* 2013;97:228-232.

27. Ganne P, Krishnappa NC, Karthikeyan KS, Raman R. Behavior of hyperreflective spots noted on optical coherence tomography following intravitreal therapy in diabetic macular edema: A systematic review and meta-analysis. *Indian J Ophthalmol.* 2021;69(11): 3208–3217.
28. Uji A, Murakami T, Nishijima K, Akagi T, Horii T, Arakawa N, et al. Association between hyperreflective foci in the outer retina, status of photoreceptor layer, and visual acuity in diabetic macular edema. *Am J Ophthalmol.* 2012;153 (4):710-717.
29. RübSam A, Wernecke L, Rau S, Pohlmann D, Müller B, Zeitz O, et al. Behavior of SD-OCT detectable hyperreflective foci in diabetic macular edema patients after therapy with anti-VEGF agents and dexamethasone implants. *J Diabetes Res.* 2021;8820216.
30. Choovuthayakorn J, Tantraworasin A, Phinyo P, Patumanond J, Kunavisarut P, Srisomboon T, et al. Factors associated with 1-year visual response following intravitreal bevacizumab treatment for diabetic macular edema: a retrospective single center study. *Int J Retina Vitreous.* 2021;7:17.